

CNS infection

Dr./ Alaa Sedky
Lecturer of Neurology
SOHAG Faculty of Medicine
30/4/2018



Objectives:

- ▶ Acute infections of the nervous system
 - ▶ early recognition, efficient decision making, and rapid institution of therapy can be **Life-saving.**
- ▶ Including acute bacterial meningitis, viral meningitis, encephalitis, focal infections such as brain abscess and subdural empyema.

Approach To The Patient

- ▶ **Nuchal rigidity ("stiff neck")** is the pathognomonic sign of meningeal irritation and is present when the neck resists passive flexion
- ▶ **Kernig's sign** is elicited with the patient in the supine position. The thigh is flexed on the abdomen with the knee flexed; attempts to passively extend the knee elicit pain when meningeal irritation is present.
- ▶ **Brudzinski's sign** is elicited with the patient in the supine position and is positive when passive flexion of the neck results in spontaneous flexion of the hips and knees.

Kernig's Sign and Brudzinski's Neck Sign



Kernig's sign. Patient supine, with hip flexed 90°. Knee cannot be fully extended.

Neck rigidity (Brudzinski's neck sign). Passive flexion of neck causes flexion of both legs and thighs.

ELSEVIER

Approach To The Patient

- ▶ The sensitivity and specificity of Kernig's and Brudzinski's signs are **uncertain**.
- ▶ Both may be **absent or reduced in very young or elderly patients, immunocompromised individuals, or patients with a severely depressed mental status.**

Acute Bacterial Meningitis

▶ Definition

- ▶ acute purulent infection within the subarach-noid space → may result in decreased consciousness, seizures, raised intracranial pres-sure (ICP), and stroke

Acute Bacterial Meningitis

▶ Epidemiology

- ▶ incidence in the US >2.5 cases/100,000 population.
- ▶ *Streptococcus pneumoniae* (~50%), *Neisseria meningitidis* (~25%), group B streptococci (~15%), *Listeria monocytogenes* (~10%), and *Haemophilus influenzae* type b (<10%)
- ▶ *N. meningitidis* is the causative organism of recurring epidemics of meningitis every 8 to 12 years.

Acute Bacterial Meningitis

Clinical Presentation

- ▶ The classic clinical triad of meningitis is fever, headache, and nuchal rigidity.
- ▶ A decreased level of consciousness occurs in >75% of patients and can vary from lethargy to coma.
- ▶ Nausea, vomiting, and photophobia are also common complaints.

Acute Bacterial Meningitis

Clinical Presentation (cont.)

- ▶ Seizures occur as part of the initial presentation of bacterial meningitis or during the course of the illness in 20-40% of patients.
- ▶ Focal seizures are usually due to focal arterial ischemia or infarction, hemorrhage, or focal edema.
- ▶ Generalized seizure activity and status epilepticus may be due to hyponatremia, diffuse edema, cerebral anoxia, or the toxic effects of antimicrobial agents.

Acute Bacterial Meningitis

Clinical Presentation (cont.)

- ▶ **Raised ICP** is an expected complication of bacterial meningitis and the major cause of obtundation and coma.
- ▶ **More than 90% of patients will have a CSF opening pressure >180mmH₂O, and 20% have opening pressures >400mmH₂O.**

Acute Bacterial Meningitis

▶ Clinical Presentation (cont.)

- ▶ Specific clinical features may provide clues to the diagnosis of individual organisms
- ▶ The most important of these clues is the **rash of meningococemia**, which begins as a diffuse **erythematous maculopapular rash** and rapidly become **petechiae** (found on the **trunk and lower extremities, mucous membranes and conjunctiva, and occasionally on the palms and soles**)

Acute Bacterial Meningitis

TABLE 164-2 CEREBROSPINAL FLUID (CSF) ABNORMALITIES IN BACTERIAL MENINGITIS

Opening pressure	>180 mmH ₂ O
White blood cells	10/μL to 10,000/μL; neutrophils predominate
Red blood cells	Absent in nontraumatic tap
Glucose	<2.2 mmol/L (<40 mg/dL)
CSF/serum glucose	<0.4
Protein	>0.45 g/L (>45 mg/dL)
Gram's stain	Positive in >60%
Culture	Positive in >80%
Latex agglutination	May be positive in patients with meningitis due to <i>Streptococcus pneumoniae</i> , <i>Neisseria meningitidis</i> , <i>Haemophilus influenzae</i> type b, <i>Escherichia coli</i> , group B streptococci
Limulus lysate	Positive in cases of gram-negative meningitis
PCR	Detects bacterial DNA

Acute Bacterial Meningitis

▶ Treatment

- ▶ The goal is to **begin antibiotic therapy within 60min** of a patient's arrival in the emergency room (before the results of CSF Gram's stain and culture)
- ▶ Due to the emergence drug resistance, empirical therapy of community-acquired suspected bacterial meningitis should include a combination of **dexamethasone + 3rd- or 4th-generation cephalosporin + vancomycin**, plus **acyclovir** (HSV encephalitis is the leading disease in the differential diagnosis), and **doxycycline** during tick season to treat tick-borne bacterial infections.

Acute Bacterial Meningitis

Prognosis

- ▶ Mortality rate is 3-7% for meningitis caused by H. influenza, N. meningitides, or group B streptococci; 15% for that due to L. monocytogenes; and 20% for S. pneumoniae.
- ▶ **Risk factors of death: decreased level of consciousness, seizures within 24h, signs of increased ICP, young age (infancy) , age >50, comorbid conditions, and delayed treatment.**

Acute Viral Meningitis

- ▶ Immunocompetent adult patients with viral meningitis usually present with **headache** (often frontal or retroorbital), **fever**, and signs of **meningeal irritation** coupled with an inflammatory CSF profile; frequently associated with photophobia and pain on moving the eyes.
- ▶ Constitutional symptoms can include **malaise, myalgia, anorexia, nausea and vomiting, abdominal pain, and/or diarrhea.**

Acute Viral Meningitis

- ▶ **Profound alterations in consciousness**, such as stupor, coma, or marked confusion, do **NOT** occur in viral meningitis and suggest the presence of encephalitis or other alternative diagnoses.
- ▶ **Seizures or focal neurologic signs or symptoms** or neuroimaging abnormalities indicative of brain parenchymal involvement are **NOT** typical of viral meningitis

Acute Viral Meningitis

- ▶ Etiology
 - ▶ CSF cultures are positive in 30-70% of patients
 - ▶ two-thirds of culture-negative cases of "aseptic" meningitis have a specific viral etiology identified by CSF PCR testing

TABLE 164-4 VIRUSES CAUSING ACUTE MENINGITIS AND ENCEPHALITIS IN NORTH AMERICA

Acute Meningitis	
Common	Less Common
Enteroviruses (coxsackieviruses, echoviruses, and human enteroviruses 68–71)	Herpes simplex virus 1
Varicella-zoster virus	Human herpesvirus 6
Herpes simplex virus 2	Cytomegalovirus
Epstein-Barr virus	Lymphocytic choriomeningitis virus
Arthropod-borne viruses	Mumps
HIV	
Acute Encephalitis	
Common	Less Common
Herpesviruses	Rabies
Cytomegalovirus ^a	Eastern equine encephalitis virus
Herpes simplex virus 1^b	
Herpes simplex virus 2	
Human herpesvirus 6	
Varicella-zoster virus	Powassan virus
Epstein-Barr virus	Cytomegalovirus ^a
Arthropod-borne viruses	Colorado tick fever virus
La Crosse virus	Mumps
West Nile virus^c	
St. Louis encephalitis virus	
Enteroviruses	

Acute Viral Meningitis

Epidemiology

- ▶ estimated that the incidence is ~60,000-75,000 cases per year.
- ▶ peak monthly incidence of about 1 reported case per 1 00,000 population.
- ▶ substantial increase in cases during the nonwinter months, reflecting the seasonal predominance of enterovirus and arthropod-borne virus (arbovirus) infections in the summer and fall

Acute Viral Meningitis

Laboratory Diagnosis – CSF examination

- ▶ typical profile: **pleocytosis, normal or slightly elevated protein concentration (0.2-0.8 g/L [20-80 mg/dL]), normal glucose concentration, and normal or mildly elevated opening pressure.**
- ▶ Organisms are **NOT** seen on Gram's stain of CSF.
- ▶ Rarely, PMNs may predominate in the first 48h of illness, especially with infections due to echovirus 9, West Nile virus, eastern equine encephalitis (EEE) virus, or mumps.

Acute Viral Meningitis

Laboratory Diagnosis – PCR

- ▶ Amplification of viral-specific DNA or RNA from CSF using **PCR amplification** has become the single most important method for diagnosing CNS viral infections.
- ▶ Diagnostic procedure for enteroviral, HSV, CMV, EBV, VZV, and HHV-6.
- ▶ PCR of stool specimens may also assist in diagnosis of enteroviral infections.

Acute Viral Meningitis

Treatment

- ▶ Treatment of almost all cases of viral meningitis is primarily **symptomatic** and includes use of analgesics, antipyretics, and antiemetics.
- ▶ Oral or IV acyclovir may be of benefit in patients with meningitis caused by HSV-1 or -2 and in cases of severe EBV or VZV infection.
- ▶ Data concerning treatment of HSV, EBV, and VZV meningitis are extremely limited.

Acute Viral Meningitis

Prognosis

- ▶ In adults, the prognosis for full recovery from viral meningitis is excellent.
- ▶ **Rare patients complain of persisting headache, mild mental impairment, incoordination, or generalized asthenia for weeks to months.**
- ▶ The outcome in infants and neonates (< 1 year) is less certain; **intellectual impairment, learning disabilities, hearing loss, and other lasting sequelae** have been reported in some studies.

Viral Encephalitis

Definition

- ▶ Viral meningitis with the infectious process and associated inflammatory response are limited largely to the meninges
- ▶ Viral encephalitis involved the brain parenchyma
- ▶ Many patients with encephalitis also have evidence of associated meningitis (**meningoencephalitis**) and, in some cases, involvement of the spinal cord or nerve roots (**encephalomyelitis, encephalomyeloradiculitis**)

Viral Encephalitis

Clinical Manifestations

- ▶ In addition to the acute **febrile** illness with evidence of meningeal involvement characteristic of meningitis, the patient with encephalitis commonly has an **altered level of consciousness** (confusion, behavioral abnormalities, or coma)
- ▶ Patients with encephalitis may have **hallucinations, agitation, personality change, behavioral disorders, and, at times, a frankly psychotic state.**

Viral Encephalitis

Clinical Manifestations (cont.)

- ▶ Focal or generalized **seizures** occur in many patients with encephalitis.
- ▶ The most commonly encountered focal findings are **aphasia, ataxia, upper or lower motor neuron patterns of weakness, involuntary movements (e.g. myoclonic jerks, tremor), and cranial nerve deficits (e.g. ocular palsies, facial weakness)**

Viral Encephalitis

Etiology

- ▶ In the United States, there are an estimated ~20,000 cases of encephalitis per year
- ▶ Hundreds of viruses are capable of causing encephalitis, only limited are identified → most commonly in immunocompetent adults are **herpes viruses** (HSV, VZV, EBV)

Viral Encephalitis

Laboratory Diagnosis – CSF Examination

- ▶ The characteristic CSF profile is **indistinguishable from that of viral men-ingitis** and typically consists of a lymphocytic pleocytosis, a mildly elevated protein concentration, and a normal glucose concentration

Viral Encephalitis

Laboratory Diagnosis – CSF PCR

- ▶ CSF PCR has become the primary diagnostic test for CNS infections caused by CMV, EBV, HHV-6, and enteroviruses

Laboratory Diagnosis – CSF culture

- ▶ CSF culture is generally of limited utility in the diagnosis of acute viral encephalitis

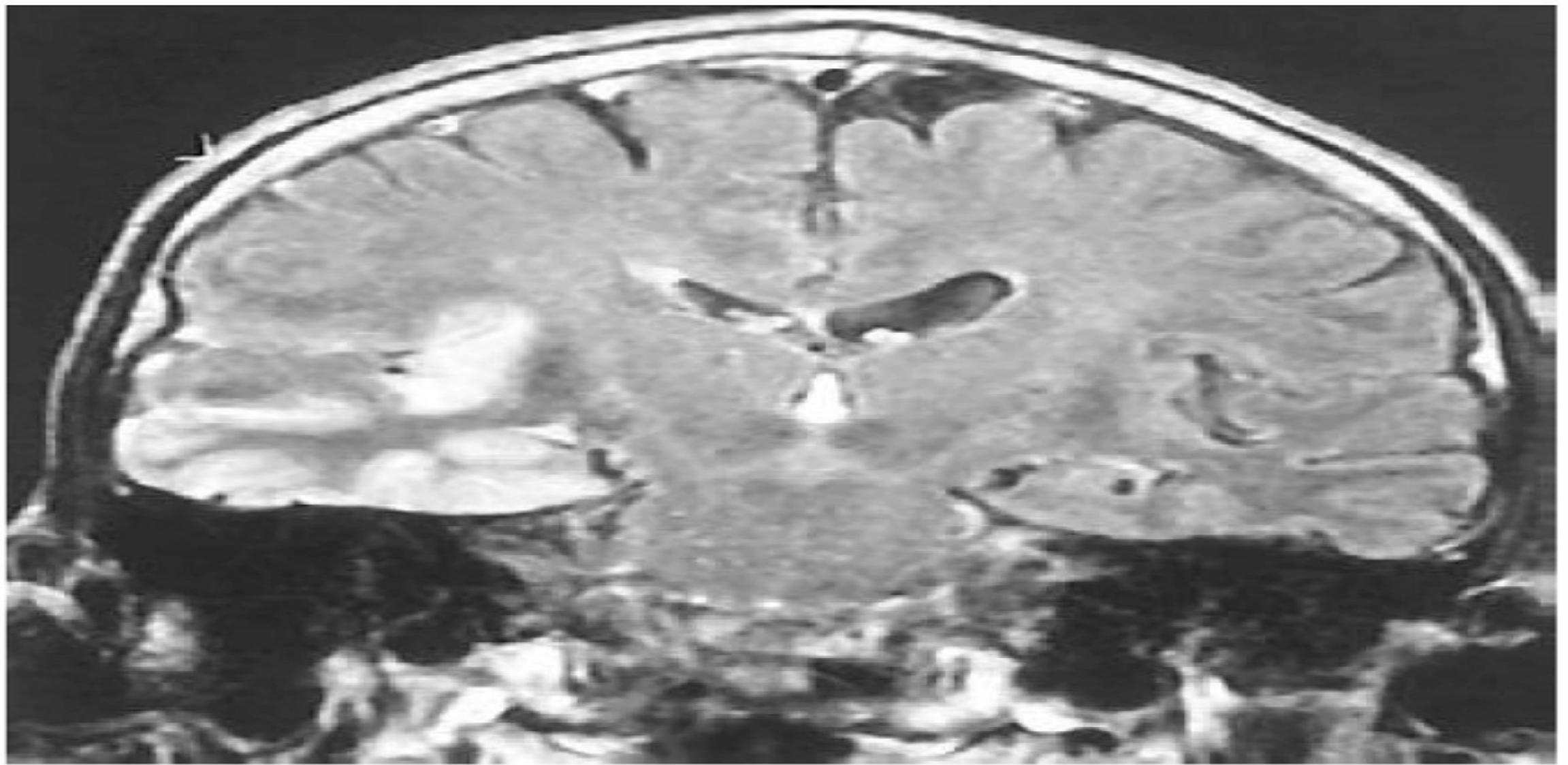


FIGURE 164-3 Coronal fluid-attenuated inversion recovery (FLAIR) magnetic resonance image from a patient with herpes simplex encephalitis. Note the area of increased signal in the right temporal lobe (*left side of image*) confined predominantly to the gray matter. This patient had predominantly unilateral disease; bilateral lesions are more common but may be quite asymmetric in their intensity.

Viral Encephalitis

Treatment

- ▶ Basic management and supportive therapy should include careful monitoring of ICP, fluid restriction, avoidance of hypotonic intravenous solutions, and suppression of fever.
- ▶ standard anticonvulsant regimens
- ▶ encephalitis patients are at risk for aspiration pneumonia, stasis ulcers and decu-bitu, contractures, deep venous thrombosis and its complications, and infections of indwelling lines and catheters

Viral Encephalitis

Treatment

- ▶ Acyclovir is of benefit in the treatment of HSV and should be started empirically in patients with suspected viral encephalitis
- ▶ Adults should receive a dose of 10mg/kg of acyclovir intravenously every 8h (30mg/kg per day total dose) for 14-21 days

Brain abscess

▶ Definition

- ▶ A brain abscess is a focal, suppurative infection within the brain parenchyma, typically surrounded by a vascularized capsule.
- ▶ The term cerebritis is often employed to describe a non-encapsulated brain abscess

Brain abscess

▶ Epidemiology

- ▶ A bacterial brain abscess is a relatively uncommon intracranial infection, with an incidence of ~0.3-1.3:100,000 persons per year.
- ▶ **Predisposing conditions** include *otitis media and mastoiditis, paranasal sinusitis, pyogenic infections in the chest or other body sites, penetrating head trauma or neurosurgical procedures, and dental infections*

Brain abscess

► Etiology

- A brain abscess may develop
 - (1) by direct spread from a contiguous cranial site of infection, such as paranasal sinusitis, otitis media, mastoiditis, or dental infection
 - (2) following head trauma or a neurosurgical procedure; or
 - (3) as a result of hematogenous spread from a remote site of infection.

Brain abscess

Clinical Presentation

- ▶ Typically presents as an expanding intracranial mass lesion
- ▶ The classic clinical triad of **headache** (>75%), **fever** (50%), and a **focal neurologic deficit** (60%). Seizure presents in 15-35% of patients.
- ▶ Hemiparesis is the most common localizing sign of a frontal lobe abscess.
- ▶ **Signs of raised ICP:** papilledema, nausea and vomiting, and drowsiness or confusion → can be the dominant presentation of some abscesses

Brain abscess

▶ Diagnosis

- ▶ Diagnosis is made by neuroimaging studies. **MRI** is better than CT for demonstrating abscesses in the early (cerebritis) stages and is superior to CT for identifying abscesses in the posterior fossa.
- ▶ Microbiologic diagnosis of the etiologic agent is most accurately determined by **Gram's stain and culture** → by CT-guided aspiration.

Brain abscess

- ▶ Diagnosis
 - ▶ **LP should not be performed** in patients with known or suspected focal intracranial infections such as abscess or empyema → increases the risk of herniation
 - ▶ CSF analysis contributes nothing to diagnosis or therapy

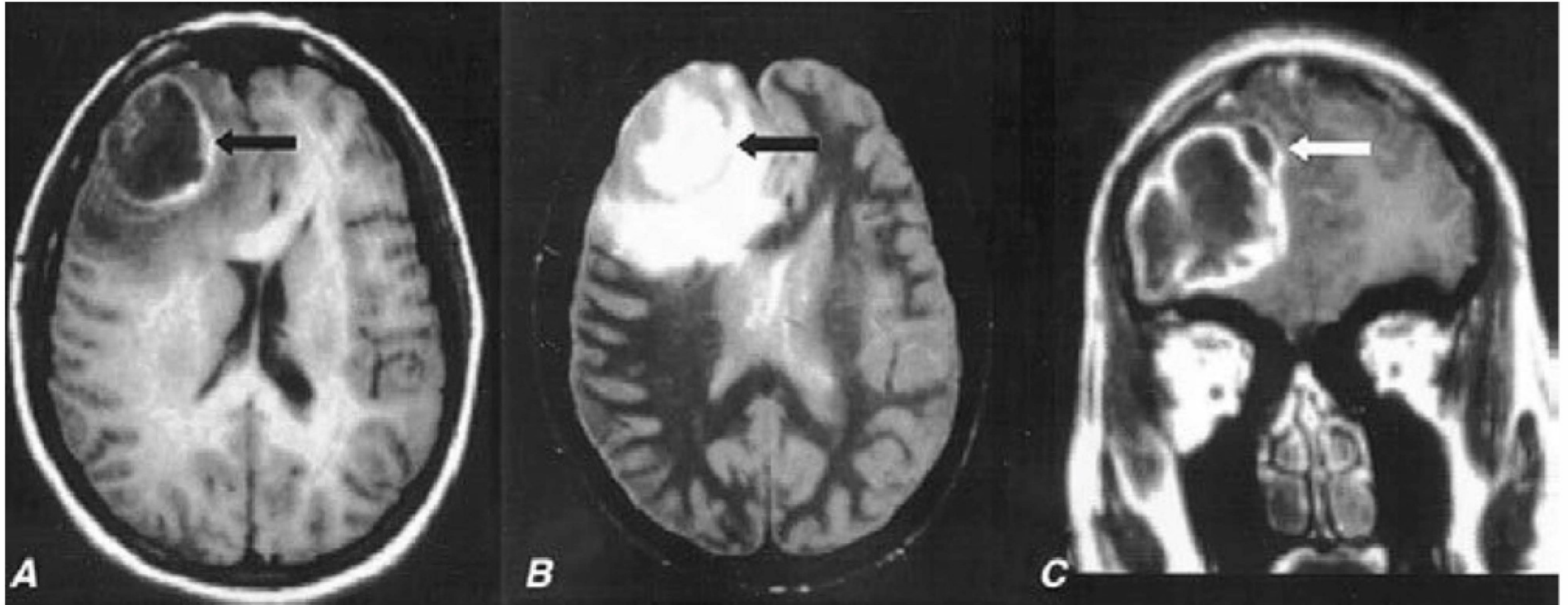


FIGURE 164-4 Pneumococcal brain abscess. Note that the abscess wall has hyperintense signal on the axial T1-weighted magnetic resonance imaging (MRI) (**A**, *black arrow*), hypointense signal on the axial proton density images (**B**, *black arrow*), and enhances prominently after gadolinium administration on the coronal T1-weighted image (**C**). The abscess is surrounded by a large amount of vasogenic edema and has a small “daughter” abscess (**C**, *white arrow*). (Courtesy of Joseph Lurito, MD; with permission.)

Brain abscess

▶ Treatment

- ▶ Optimal therapy of brain abscesses involves a combination of high-dose parenteral antibiotics and neurosurgical drainage.
- ▶ typically includes a **3rd- or 4th-generation cephalosporin** and **metronidazole**. **Vancomycin** for coverage of staphylococci
- ▶ **Aspiration and drainage** of the abscess are beneficial for both diagnosis and therapy

Brain abscess

▶ Treatment

- ▶ Complete excision of a bacterial abscess via craniotomy or craniectomy is generally reserved for multiloculated abscesses or those in which stereotactic aspiration is unsuccessful
- ▶ Medical therapy alone should be reserved for neurosurgically inaccessible, small, or nonencapsulated abscesses
- ▶ All patients should receive a minimal of 6-8 weeks of parenteral antibiotics therapy

Brain edema

Definition: excess accumulation of fluid in the intracellular or extracellular spaces of the brain.

Symptoms: include

- ▶ Nausea, vomiting, blurred vision,
- ▶ In severe cases, seizures and coma.
- ▶ If brain herniation occurs, respiratory symptoms or respiratory arrest can also occur due to compression of the respiratory centre.

Brain edema

Causes

- ▶ Brain trauma
- ▶ Non-traumatic causes such as stroke, tumour, CNS infection or metabolic causes.

Brain edema

Types

1. Vasogenic
2. Cytotoxic
3. Interstitial

Vasogenic brain edema

- ▶ **due to a breakdown of the tight endothelial junctions that make up the blood–brain barrier.**
- ▶ **As water enters white matter, it moves extracellularly along fiber tracts and can also affect the gray matter.**
- ▶ **This type of edema may result from trauma, tumors, focal inflammation, late stages of cerebral ischemia and hypertensive encephalopathy.**

Cytotoxic brain oedema

- ▶ **The blood–brain barrier remains intact but a disruption in cellular metabolism impairs functioning of the sodium and potassium pump in the glial cell membrane, leading to cellular retention of sodium and water.**
- ▶ **It can occur in Reye’s syndrome, early ischemia, cardiac arrest, and pseudotumor cerebri.**

Interstitial brain edema

- ▶ **Interstitial edema occurs in obstructive hydrocephalus due to a rupture of the CSF–brain barrier.**

Treatment of brain edema

- ▶ Treatment of the cause.
- ▶ Osmotherapy using Mannitol, diuretics
- ▶ Surgical decompression to allow the brain tissue room to swell without compressive injury.

Thank you for your attention!